

Review Paper: Role of the Popliteal Fossa in Knee Problems: Theoretical Considerations and Practical Implications

Maghsoud Eivazi Gh¹, Amin Alilou², Sara Fereydounnia^{3*} , James Selfe⁴, Sahar Zamani⁵ 

1. Faculty of General Medicine, Azerbaijan Medical University, Baku, Azerbaijan.

2. Faculty of Dentistry, Azerbaijan Medical University, Baku, Azerbaijan.

3. School of Rehabilitation, Tehran University of Medical Sciences, Tehran, Iran.

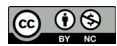4. Department of Allied Health Professions, Faculty of Health, University of Central Lancashire, Preston, England.

5. School of Rehabilitation Sciences, Shahid Beheshti University of Medical Sciences, Tehran, Iran.



Citation: Eivazi Gh M, Alilou A, Fereydounnia S, Selfe J, Zamani S. Role of the Popliteal Fossa in Knee Problems: Theoretical Considerations and Practical Implications. Journal of Modern Rehabilitation. 2020; 14(3):131-140. <http://dx.doi.org/10.18502/jmr.v14i3.7711>

 <http://dx.doi.org/10.18502/jmr.v14i3.7711>



Article info:

Received: 13 Jan 2020

Accepted: 05 May 2020

Available Online: 01 Jul 2020

Keywords:

Posterolateral corner of the knee, Popliteus Fossa, Popliteomeniscal fascicles, Injury

ABSTRACT

The popliteal fossa is located at the back of the knee joint and it is an area where blood vessels and nerves and also lymph nodes pass. Popliteal fossa injuries includes nearly 2% of acute knee injuries. The treatment of chronic injuries are always more difficult than acute ones, because its diagnosis would depend on careful interpretation of specific clinical exams. In this review, we describe our current understanding of role of popliteal fossa in knee problems, and summarize the anatomy and functional role of popliteal fossa and popliteomeniscal fibers, and mechanism of popliteomeniscal fibers injuries, and discuss strategies for diagnosis of popliteomeniscal fibers lesions, differential diagnosis, and treatment of the posterolateral corner injuries.

1. Introduction

The popliteal fossa is an important area between the thigh and leg which is the main area for passing the neurovascular structures from thigh to leg and vice versa. This fossa is a lozenge shaped space which is located at the posterior aspect of the knee joint between the posterior compartment muscles of thigh and leg. The main contents of the popliteal fossa include the popliteal artery, popliteal vein, tibial and common fibular nerves. The floor of the

fossa is covered by the knee joint capsule and the ceiling is covered by superficial fascia and skin [1, 2].

The popliteus muscle contains many muscle spindles which are arranged in complex form [3]. The most part of its kinaesthesia is monitoring the locking and unlocking of human knee joint [4]. Therefore, it can be concluded that in case of any injury in the ligaments insertion of popliteus muscle, the locking and unlocking mechanism is likely to be disturbed. In other words, it may disrupt the overall function of the knee.

* Corresponding Author:

Sara Fereydounnia, PhD. & PT.

Address: School of Rehabilitation, Tehran University of Medical Sciences, Tehran, Iran.

Tel: +98 (21) 77533939

E-mail: s-fereydounnia@razi.tums.ac.ir

Popliteal fossa injuries account for nearly 2% of acute knee injuries [5]. However damages to the posterolateral elements of the knee are relatively rare, but are becoming progressively diagnosed in isolation or more commonly as a part of combined injuries in this region. Since, the treatment of chronic injuries are always more difficult than acute [6], but diagnosis and treatment is not so easy because it would depend on careful interpretation of specific clinical exam [7-9] which it seems difficult as well when posterolateral injuries occur in combined formats.

Diamntopoulos et al. claimed that clinically undetected posterolateral corner injuries have been responsible for surgical failure following ACL or PCL repair/reconstruction or chronic knee discomfort after traumatization [10] (Figure 1).

Brandt states that ligamentous lesions may help promote the development of osteoarthritis by the creating instability and joint laxity [11]. Medial and lateral collateral ligaments protect the knee joint against valgus and varus stresses respectively [11]. Knee collateral ligament injuries are considered a risk factor for development of osteoarthritis in human subjects [11-14]. Ligamentous laxity in associated with hypermobility syndrome was considered another recognized risk factor in the knee osteoarthritis [11]. According to Gale's study, meniscal subluxation in patients with knee osteoarthritis has been reported as significantly higher than asymptomatic control subjects.

They also have shown the presence of correlation with the amount of meniscal subluxation and joint space narrowing in the medial or lateral part of the knee. The connection of the meniscus with bony and surrounding soft tissues has a complex arrangement and may have a role in prevention of the meniscal subluxation [15]. Based on the above observations, popliteus muscle hypofunction or its ligamentous shortness and inactivity may have a role in contributing to meniscal subluxation and knee osteoarthritis development. Therefore, we aimed to investigate the role of popliteomeniscal fascicles in developing of the knee problems.

2. Anatomy and the Functional Role of the Popliteal Fossa and Popliteomeniscal Fibers

According to the report of Grood et al., the upper wall of popliteus fossa consists of superior popliteomeniscal fascicles and its lower wall is made of lower popliteomeniscal fascicles. The Medial wall is shaped by the lateral meniscus itself and the lateral wall is completed by the popliteus tendon [16]. Popliteomeniscal fibers are composed of two fascicles which are combined with the lateral meniscus. The first fascicle which make the floor of popliteus fossa and mostly covered by synovial tissue [17] is connected inferiorly with the middle third of the lateral meniscus and ventrally linked to the popliteus tendon. The second fascicle in the upper section is combined with posterior horn of lateral meniscus and builds

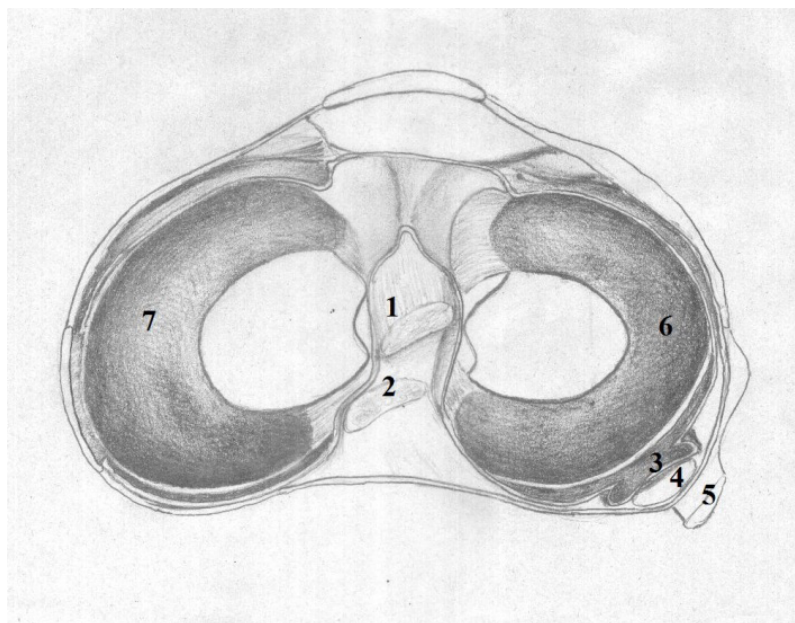
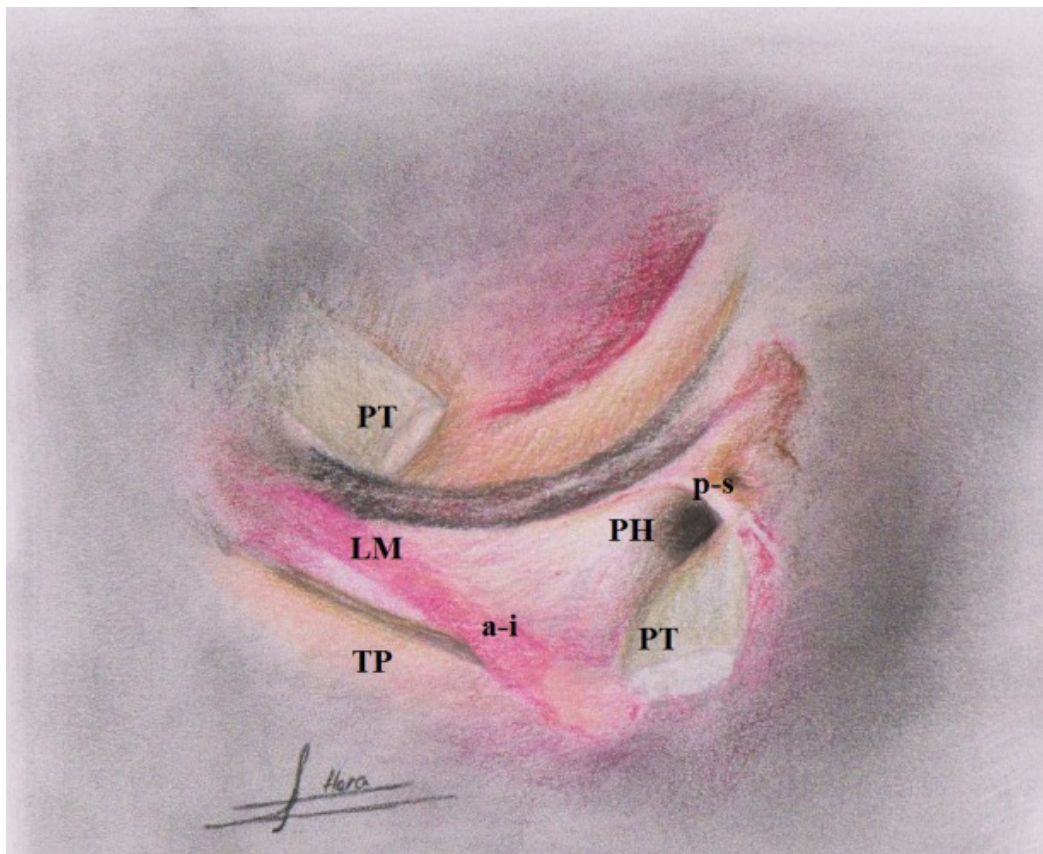


Figure 1. Schematic representation from superior view of top of right tibia

1. Anterior cruciate ligament; 2. Posterior cruciate ligament; 3. Popliteus tendon; 4. Arcuate ligament; 5. Posterior 1/3 lateral capsular ligament; 6. Lateral meniscus; 7. Medial meniscus.



JMR

Figure 2. The antero-inferior popliteomeniscal fascicle

A-I: Makes the floor of the popliteal hiatus and the posterior-superior popliteomeniscal fascicle; P-S: makes the roof of the popliteal hiatus. Popliteus Tendon (PT) had been cut and reflected to illustrate clearly the role of 2 popliteomeniscal fascicles.

LM: Lateral Meniscus; TP: Tibial Plateau; PH: Popliteal Hiatus. Redrawn after Diamantopoulos et al. [10].

the roof of popliteus fossa. It seems that anterior-inferior popliteomeniscal fascicles are stronger and thicker than postero-superior popliteomeniscal fascicles (Figure 2). According to the report of Suganuma et al., abnormal popliteomeniscal fibers increase the risk of locking and recurrent subluxation of the lateral meniscus [17].

Ullrich et al. and Terry and Laprade have also reported the existence of third popliteomeniscal fascicle in their anatomic studies which is connected to the posterior horn of the lateral meniscus. This fascicle is called “postero-inferior popliteomeniscal” [18-20]. Sussmann et al. believed that the fascicle’s task is to provide a vascular supply to the lateral meniscus in the area which there is no capsular connectivity. In addition these researchers showed that the structural relationship between the popliteus tendon and lateral meniscus can help in stabilization of the area [21].

According to the report of Arnoczky and Warren the posterolateral part of the lateral meniscus has no perme-

able peripheral vascular near the popliteus tendon. This part of lateral meniscus gains nutrition via a ventral pedicle of synovial tissue which is provided through circular micro-vascular to the lateral septum of meniscus. This area is also feed by the micro vascular branches which are carried by the popliteomeniscal fascicles [22, 23]. These fascicles are composed of three layers: a dense collagen layer, a vascular layer and a capsular or synovial layer. These fascicles are involved in stabilization of lateral meniscus furthermore they help the popliteus tendon in retracting the lateral meniscus [21].

Based on their view, this area of the meniscus is known as the “bare area”. Bare area is limited by two tendons of the popliteomeniscal ligament; upper tendon (superomedial) which is connected to the upper edge of lateral meniscus and the lower tendon (infero-lateral) which is joined to the popliteofibular ligament, posterior horn of meniscus and coronary ligament [22, 23]. Jae-hynk

Yang et al. reported that the bare part of the lateral meniscus in their study samples was more than 1.5 cm [24].

Simonian et al. illustrated that the functions of popliteomeniscal ligaments are as the stabilizer of the lateral meniscus and in the case of ligament rupture, the mobility of the lateral meniscus would increase. They suggested that disturbances in the amount of mobility of the lateral meniscus with hypofunction, adherence and shortness of the ligaments could lead to a disorder in function of the knee. The differences in the form of attachment and the amount of thickness of postero-superior and antero-inferior popliteomeniscal fascicles may explain their different roles in making the lateral meniscus stability. Antero-inferior fascicles which attached to the base of the meniscus compared with postero-superior fascicles are narrower and may play the more significant role in the lateral meniscus stability. Therefore, the amount of the lateral meniscus displacement is controlled by antero-inferior fascicles more than postero-superior fascicles [25].

Sta and Birrer [26] recommended that three types of popliteomeniscal fascicles (antero-inferior, postero-superior and postero-inferior) in combination with popliteus tendon form a ring-like peripheral connection with the lateral meniscus in the popliteus fossa zone. At least one part of popliteus complex has less movement through the popliteomeniscal fascicles compared with other areas of lateral meniscus which is inside of the popliteus fossa so this enables additional stability. The necessity of normal and safe static and dynamic connection between lateral meniscus and popliteus tendon is the role of popliteomeniscal fascicles in control of lateral meniscus motion during knee flexion and extension [26-30].

Due to Suganuma et al. there is not a specific definition for degree of normality of the popliteomeniscal fiber in Magnetic Resonance Imaging (MRI) and arthroscopy. These researchers also speculated that repeated submaximal traumas created by the knee varus along with medial unicompartmental knee osteoarthritis and the aging process, may affect its structure and physical properties [17]. According to these researchers the existence of any abnormality may predispose the patient to the symptoms of knee locking. Hence, they considered abnormality of inferior popliteomeniscal fibers as a precondition for knee instability. According to their opinion insufficiency in popliteomeniscal fibers can be the result of the lateral meniscus locking or recurrent subluxation of the lateral meniscus and not vice versa [17].

3. Mechanism of Popliteomeniscal Fibers Injuries

Most likely a combination of the hyper-extension and varus force exertion is involved in damage of the posterolateral structures of the knee. Other mechanism is simultaneously exertion of force in the direction of tibial external rotation and hyperextension [31].

Posterolateral injuries can occur in isolation but they are often associated with the Posterior Cruciate Ligament (PCL) and Anterior Cruciate Ligament (ACL) injuries or both [31]. Sport injuries, car accidents and falls are the most common causes of injuries [31]. The presence of Trigger Points (TrPs) in the popliteus muscle may also be an aggravating factor which increases in playing football, running, twisting, and slipping especially on ski slopes. TrPs in this muscle often results from or are perpetuated by an acute or chronic overuse of the muscle, excessive foot subtalar joint pronation, wearing high- heeled shoes, and a torn posterior cruciate ligament. TrPs in the popliteus may produce knee pain when crouching or walking/running downhill or down- stairs, or decreased lateral rotation or extension of the leg at the knee joint.

The referral patterns of popliteus TrPs must be distinguished from the referral patterns of TrPs in the gastrocnemius, soleus, plantaris, hamstrings, and gluteus minimus. TrPs in this muscle are often incorrectly assessed as Baker's cyst, instability of the knee joint, popliteus tendinitis/tenosynovitis, meniscal tear, or torn plantris muscle. The popliteus belly and its proximal attachment should be palpated for examination of trigger points [4, 32, 33]. The popliteomeniscal ligaments maybe particularly overloaded with the braking forward movement of the femur on tibia during the rotation of the trunk during weight bearing on the semi-flexed knee on the rotation side. Trauma or strain which causes PCL injury may also cause overload and strain of these ligaments [4].

Brody et al. have reported a correlation between excessive foot pronation in weight bearing activity, and the aggravation of damage and signs of popliteus tendinitis [34]. Additional pronated foot causes the tibia to be in external rotation stressing the popliteus, so it could intensify trigger points of popliteus muscle. Therefore, any abnormalities or imbalances in the lower extremity, leg length discrepancy and biomechanical imbalance should be considered and be corrected by using orthotic devices [34]. Holmes et al. have reported that leg length discrepancy more than a quarter of an inch (6.4 mm) has clinical significance [35].

4. Diagnosis of Popliteomeniscals Fiber Lesions

Signs

Most of the patients with the popliteus complex disorders are suffering from pain in the posterior aspect of the knee during bending, running, hiking and specially walking down and up the stairs. Patients who suffer from trigger point's pain in the popliteus muscle rarely complain of knee pain during the night. They have slight limitation in the range of flexion and extension of the knee or sometimes there is weakness in medial rotation of the leg [4].

Examination

Distinguishing between single popliteomeniscal damage and other knee injuries are often very difficult. The patients who are often referred to physiotherapy clinics have chronic disorders. Disease presence may be associated with joint line pain of the knee near the medial or lateral aspects or may be associated with instability [7, 31]. This instability is often associated with hyper extension problems and will be intensified while walking down and up the stairs. Instability is also determined by external rotation that causes posterior displacement of the lateral tibial plateau. This movement is called 'posterolateral rotatory instability' by Hughston et al. [7, 31].

Observation

The knee must be examined specially in the posterolateral aspect for any swelling, soreness, bruising and tenderness [31, 36]. Based on the experience of the authors, the patients are more sensitive to deep palpation in this area rather than having tenderness.

Patient's gait

In acute injuries when the patient has an antalgic gait the examination of the patient is not necessary. However, in chronic cases the examination of gait and alignment of the lower extremity is considered as an important part of the examination. Some patients may have a slight knee flexion during walking which usually cannot be detected without a careful examination. The antalgic position of semi-flexion during walking may be for avoiding the pain, the occurrence of instability in the knee or further stress on the joint and joint capsule in the hyper extension position [37].

Palpation

The simple way to palpate popliteomeniscal ligaments is that the patient sits in the position in which the ankle is on the opposite knee (Figure 3). The Lateral epicondyle

of the femur is identified and marked first. By using the pads of fingers, the insertion of popliteus muscle with using the landmark of the lateral epicondyle and palpating about 0.5 cm distal and 0.5 cm anterior toward this prominence is palpable. The tendon inserts between the Lateral Collateral Ligament (LCL) and capsule and it is rarely separable from other adjunct structures. Therefore, there is a possibility of localization by using slight active rhythmic flexion and extension of the knee. In this case, the muscle contraction can be felt under the palpating finger. Another structure which could be identified for more localization is the head of fibula.

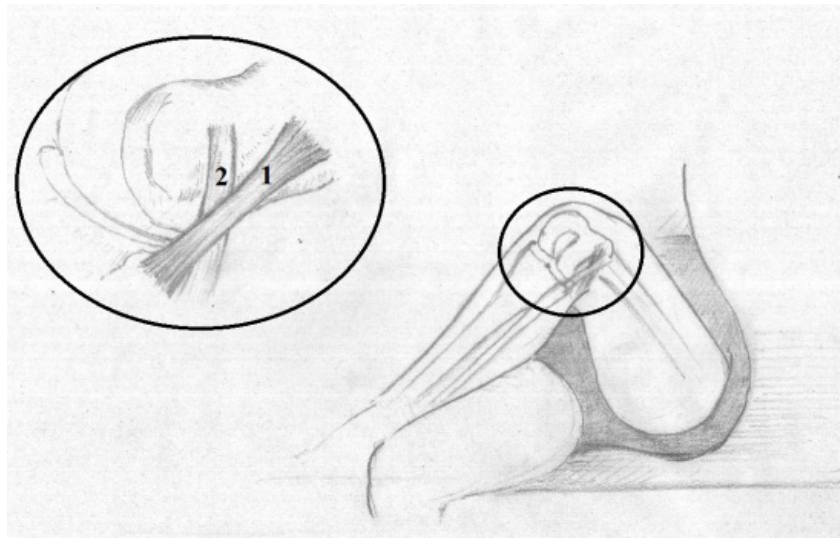
The anterior, posterior and proximal part of the head of fibula using a vertical palpation technique is identified. It is necessary to identify the top head of fibula which is the location of LCL insertion and part of the biceps tendon. The knee should be in the Patrick test position for exact palpation [38]. It means that the leg must be in flexion, abduction and lateral rotation and be over the other leg. With a valgus force on the joint the exerted tension on LCL increases and the prominence becomes bigger. The third structure which should be used for localization and palpating of popliteomeniscal ligaments is the lateral joint line of the knee and lateral meniscus [38]. We can palpate the Fibular Collateral Ligament (FCL) and then touch a localized tenderness exactly posterior to the FCL along with the tendon and its junction with lateral joint line.

5. The Method of Slight Knee Flexion Diagnosis (Bent Knee)

For this purpose, the patient lies supine on the table and keeps his/her knees in the maximally pulled and extended position. The therapist stands at the end of the table near the patient's feet. He/she puts both palms of hands on both patellas on the way that the fingers tip is cranial. Pressure of both hands should be gentle and should be avoided from applying heavy pressure on the both knees. In most cases, slight flexion of the knee can be detected by using height difference of both hand (Figure 4A).

6. The Diagnosis Test of Limitation in Knee Flexion at the end of Flexion in Prone Position

The patient lies in the prone position. A pillow is placed under the pelvis to avoid low back hyper extension. Then the patient is asked to bend his/her both knees in flexion simultaneously. The therapist who is standing at the end of table puts his/her both hands palm on the posterior aspect of heels. The hands are



JMR

Figure 3. Schematic representation of manner of palpation

1. Lateral Collateral Ligament (LCL); and 2. Popliteus tendon as immersed in the front of anterior aspect of LCL in the figure of 4-position. Redrawn based on Reichert B, Stelzenmueller W.: Palpation Techniques: Surface Anatomy for Physical Therapists: Thieme; 2011 [38].

placed on the back of heels so that the dorsum of hand is cranial. The slight limitation of flexion of both knees could be realized (Figure 4B).

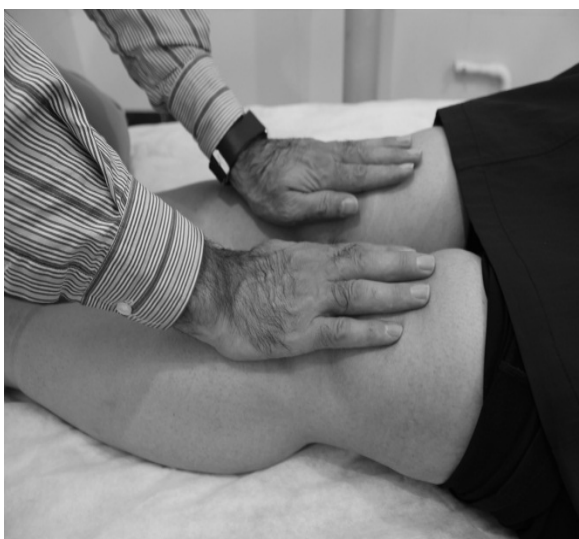7. Magnetic Resonance Imaging (MRI)

Superior popliteomeniscal fascicle may be abnormal because of rupture or the lack of it in MRI imaging.

However, we cannot be sure that lack of resolution of popliteomeniscal fascicle in MRI is the result of its rupture or edema [39].

Pavlov and Goldman argue that edema and adhesion may be the cause of difficulty in observation of popliteomeniscal fascicles in knee arthrography [40]. The detection of abnormally in the fascicles may indicate the

A



B

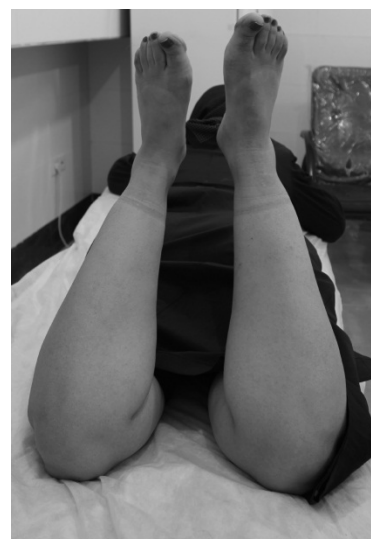

Figure 4. A simple technique for diagnosing of mild knee limitation

JMR

A: Created following knee problem due to some structural injuries around the knee including popliteus tendon complexes (supine); B: Prone. In this figure, the therapist's hands are not shown to better show the limitation of the right knee flexion.

existence of rupture in the lateral meniscus. It was also claimed that abnormal superior popliteomeniscal fascicles proposed as a cause for rupture of lateral meniscus, however, it is not pathogenomic [41, 42].

8. Popliteomeniscal Ligament Involvement

In the case of strain or injury of Popliteomeniscal ligament, it is possible to palpate and friction massaged the ligament in the interface of popliteus tendon and lateral joint line of the knee in the posterior aspect of the fibular collateral ligament (FCL). For this purpose while ankle is on the opposite knee, the index finger is placed under the middle finger and the area is friction massaged transversely with a short-acting reciprocating motion [43]. To find the exact position of ligaments the patient is asked to resist against to medial rotation force of the hand on the distal side of the foot. The exact position of injury is easily palpable with this functional test [43].

9. Differential Diagnosis

The patients who present the complaints of the popliteomeniscal fiber lesions, are likely to have one of the four conditions in acute phase: popliteal vein thrombosis, antero-medial and postero-lateral instability, avulsion of popliteus tendon, and meniscus or posterior capsule rupture of knee joint. Also, the therapist should consider the Baker's cyst, biceps femoris tendinitis, ilio-tibial band friction syndrome, and peroneal nerve entrapment as the differential diagnosis of the popliteomeniscal fiber lesions in chronic conditions. Therefore, this injury is complex and has a wide differential diagnosis. An awareness of the certain patterns and a good examination can help the therapist identify the dysfunction and its underlying causes [4, 44].

10. Treatment of Postero-Lateral Corner Injuries

In posterolateral corner of the knee injuries it is not an easy task to decide which patient should be treated by surgery and which one with conservative methods [45]. If the popliteomeniscal ligament injuries are in the form of the single type and have sustained a low grade injury, it may respond to conservative treatment [31]. According to some studies, non-surgical treatment of the mild to moderate damage in the posterolateral corner of the knee have had a good outcome but in severe damages the outcome and result are not very satisfactory [12, 31].

According to Davies et al., single injury of the posterolateral corner of the knee is rare and almost all their injuries were associated with ACL or PCL injuries or both

of them [31, 46]. Considering the fact that the majority of referring cases are non-surgical cases, therefore this paper focuses on non-surgical procedures. In this section conventional conservative methods which are applicable in manual therapy are briefly described:

11. Dimensional Myofascial Release Technique

Giammatteo has explained the therapeutic procedures as follows:

1- The patient lies in prone position. Both hands of therapist are placed on the belly of popliteus muscle and lateral condyle of femur in the vicinity of each other. Shift the muscle in three directions (and in three planes) and displace in indirect manner.

2- First plane: move the muscle in inferior and superior direction. Move to the easier side.

3- Second plane: "stack" motion of second plane to it. Move the muscle in medial or lateral direction. Move to the easier side.

4- Third plane: "add" the third plane now. Move the muscle in a clockwise direction and vice versa. Move to the easier side.

5- Release: maintain the created fulcrum in step1-4. When firmness of tissue is unwind, the motion is happen in the body's internal environment. Keep your hands fixed furthermore and avoid release fulcrum [30].

12. Articular Myofascial Release Technique in Popliteomeniscal Ligaments

This technique is used in the hypo mobility of knee joint in flexion or extension. Put both hands on both sides of the knee joint line and its posterolateral aspect. Hands must be put next to each other to keep control over the two joint surfaces. Avoid distraction or approximation of joint surfaces. Move the hands in opposite directions in three planes of sagittal, coronal and horizontal. In sagittal plane, move on joint surface, superior-inferior direction. Then move the joint surface in opposite direction. Move a joint surface in medial rotation direction and the other joint surface in lateral rotation direction (medial-lateral). Move the joint surface in adduction direction and the other joint surface in abduction direction in coronal plane [47].

13. Discussion

According to the arthroscopic study of Staübli and Birrer, popliteus tendon and popliteomeniscal fascicles which are connected to the lateral meniscus form a functional unit that participates in the controlling of valgus and varus angulation [26]. When a heavy trauma occurs to the knee area, secondary structures are sacrificed first to avoid the main structures lesions. It means that these structures act as a kind of buffer or safety valve. They believe that the extent of structural damages in popliteomeniscal fascicles and their effect on controlling of the meniscal movement are determinant factor in posterolateral pain of the knee. The rupture and complete damage of popliteomeniscal and popliteofibular cause the loss of their inhibitory and controlling function. This rupture is sometimes associated with popliteus tendon downward movement and medial displacement of lateral meniscus [26].

Garrick and Webb believe that excessive tiredness of quadriceps is the underlying cause of popliteus muscle components and elements involvements [48]. The authors believe this is the same phenomenon that occurs while walking with bent knee position. It means that quadriceps muscle is engaged in continues activity in all walking phases because of physiological unlocking of the knee. This phenomenon could lead to excessive tiredness of quadriceps and finally could lead to the insufficiency of popliteus muscle and its components [40].

Physical therapy for the postero-lateral corner injuries involves a thorough subjective and objective evaluation and assessment of the entire lower extremity from the hip to the foot. Then the physical therapist can prescribe the right treatments- including manual therapy, exercises, and modalities- to help decrease the knee pain and improve the overall mobility and gait.

14. Conclusions

The damage of posterolateral structures of the knee is common and often they are associated with ACL and PCL ruptures. The damage of individual and singular posterolateral aspects of the knee is rare and uncommon. According to clinical experiences of the authors the aim of the conservative treatment must be the treatment of all elements and components in which there is probability of lesion in this zone. In this paper we have focused on the constituent elements of popliteus fossa due to the importance of the subject. The patient could return to normal functional activities after treatment.

Ethical Considerations

Compliance with ethical guidelines

All ethical principles are considered in this article. The participants were informed about the purpose of the research and its implementation stages; they were also assured about the confidentiality of their information; moreover, they were free to leave the study whenever they wished, and if desired, the research results would be available to them.

Funding

This research did not receive any specific grant from funding agencies in the public, commercial, or non-profit sectors.

Authors' contributions

All authors were equally contributed in preparing this article.

Conflict of interest

The authors declared no conflict of interest.

Acknowledgements

We would like to express our special thanks to all authors who have contributed in this article.

References

- [1] Drake R, Vogl W, Mitchell A. Gray's anatomy for students Elsevier. London: Churchill Livingstone; 2005.
- [2] Gray H, Standring S. Gray's anatomy: The anatomical basis of clinical practice. London: Churchill Livingstone; 2008.
- [3] Amonoo-Kuofi H. Morphology of muscle spindles in the human popliteus muscle. *Cells Tissues Organs*. 1989; 134(1):48-53. [DOI:10.1159/000146732] [PMID]
- [4] Simons DG, Travell J, Simons LS. Myofascial pain and dysfunction: The trigger point manual. volume 1. 2nd edition. Philadelphia: Williams & Wilkins; 1999. [DOI:10.1016/S0161-4754(99)70079-5]
- [5] Haslam P, Bickerstaff D. Postero-lateral rotatory instability. *Current Orthopaedics*. 2007; 21(6):451-6. [DOI:10.1016/j.cuor.2007.07.008]
- [6] Djian P. Posterolateral knee reconstruction (Ligamentoplasties postéro-latérales du genou) [French]. In: Conférences d'enseignement 2014: Amsterdam: Elsevier; 2014. pp.225-39. [DOI:10.1016/B978-2-294-74506-5.00018-7]

- [7] Hughston JC, Jacobson K. Chronic posterolateral rotatory instability of the knee. *Journal of Bone and Joint Surgery: JBJS*. 1985; 67(3):351-9. [DOI:10.2106/00004623-198567030-00001]
- [8] LaPrade RF, Wentorf FA, Fritts H, Gundry C, Hightower CD. A prospective magnetic resonance imaging study of the incidence of posterolateral and multiple ligament injuries in acute knee injuries presenting with a hemarthrosis. *Arthroscopy: The Journal of Arthroscopic & Related Surgery*. 2007; 23(12):1341-7. [DOI:10.1016/j.arthro.2007.07.024] [PMID]
- [9] LaPrade RF, Terry GC. Injuries to the posterolateral aspect of the knee: association of anatomic injury patterns with clinical instability. *The American Journal of Sports Medicine*. 1997; 25(4):433-8. [DOI:10.1177/036354659702500403] [PMID]
- [10] Diamantopoulos A, Tokis A, Tzurbakis M, Patsopoulos I, Georgoulis A. The posterolateral corner of the knee: Evaluation under microsurgical dissection. *Arthroscopy: The Journal of Arthroscopic & Related Surgery*. 2005; 21(7):826-33. [DOI:10.1016/j.arthro.2005.03.021] [PMID]
- [11] Brandt K D, Radin E L, Dieppe P A, van de Putte L. Yet more evidence that osteoarthritis is not a cartilage disease. *Annals of the Rheumatic Diseases*. 2006; 65(10):1261-4. [DOI:10.1136/ard.2006.058347] [PMID] [PMCID]
- [12] Kannus P. Nonoperative treatment of grade II and III sprains of the lateral ligament compartment of the knee. *The American Journal of Sports Medicine*. 1989; 17(1):83-8. [DOI:10.1177/036354658901700114] [PMID]
- [13] Burr D, Radin E. Trauma as a factor in the initiation of osteoarthritis. Cartilage changes in osteoarthritis: Indiana University. School of Medicine Press, Indianapolis, IN; 1990. pp. 73-80.
- [14] Kannus P. Long-term results of conservatively treated medial collateral ligament injuries of the knee joint. *Clinical Orthopaedics and Related Research*. 1988; (226):103-12. [DOI:10.1097/00003086-198801000-00015]
- [15] Gale D, Chaisson C, Totterman S, Schwartz R, Gale M, Felson D. Meniscal subluxation: Association with osteoarthritis and joint space narrowing. *Osteoarthritis and Cartilage*. 1999; 7(6):526-32. [DOI:10.1053/joca.1999.0256] [PMID]
- [16] Grood ES, Stowers SF, Noyes FR. Limits of movement in the human knee: Effect of sectioning the posterior cruciate ligament and posterolateral structures. *Journal of Bone and Joint Surgery: JBJS*. 1988; 70(1):88-97. [DOI:10.2106/00004623-198870010-00014]
- [17] Sukanuma J, Mochizuki R, Inoue Y, Yamabe E, Ueda Y, Kanauchi T. Magnetic resonance imaging and arthroscopic findings of the popliteomeniscal fascicles with and without recurrent subluxation of the lateral meniscus. *Arthroscopy: The Journal of Arthroscopic & Related Surgery*. 2012; 28(4):507-16. [DOI:10.1016/j.arthro.2011.08.311] [PMID]
- [18] Terry GC, LaPrade RF. The posterolateral aspect of the knee: Anatomy and surgical approach. *The American Journal of Sports Medicine*. 1996; 24(6):732-9. [DOI:10.1177/036354659602400606] [PMID]
- [19] Ullrich K, Krudwig WK, Witzel U. Posterolateral aspect and stability of the knee joint. I. Anatomy and function of the popliteus muscle-tendon unit: An anatomical and biomechanical study. *Knee Surgery, Sports Traumatology, Arthroscopy*. 2002; 10(2):86-90. [DOI:10.1007/s00167-001-0268-5] [PMID]
- [20] Veltri DM, Deng XH, Torzilli PA, Maynard MJ, Warren RF. The role of the popliteofibular ligament in stability of the human knee: A biomechanical study. *The American Journal of Sports Medicine*. 1996; 24(1):19-27. [DOI:10.1177/036354659602400105] [PMID]
- [21] Sussmann PS, Simonian PT, Wickiewicz TL, Warren RF. Development of the popliteomeniscal fasciculi in the fetal human knee joint. *Arthroscopy: The Journal of Arthroscopic & Related Surgery*. 2001; 17(1):14-8. [DOI:10.1053/jars.2001.19653] [PMID]
- [22] Arnoczky SP, Warren RF. Microvasculature of the human meniscus. *The American Journal of Sports Medicine*. 1982; 10(2):90-5. [DOI:10.1177/036354658201000205] [PMID]
- [23] Arnoczky SP, Warren RF. The microvasculature of the meniscus and its response to injury: An experimental study in the dog. *The American Journal of Sports Medicine*. 1983; 11(3):131-41. [DOI:10.1177/036354658301100305] [PMID]
- [24] Yang J-H, Jeong H-I, Kim T-S, Park S-C, Yoon J-R. The management of the popliteus hiatus during lateral meniscal transplantation. *The Knee*. 2012; 19(6):959-61. [DOI:10.1016/j.knee.2012.04.007] [PMID]
- [25] Simonian PT, Sussmann PS, Wickiewicz TL, Potter HG, van Trommel M, Weiland-Holland S, et al. Popliteomeniscal fasciculi and the unstable lateral meniscus: Clinical correlation and magnetic resonance diagnosis. *Arthroscopy: The Journal of Arthroscopic & Related Surgery*. 1997; 13(5):590-6. [DOI:10.1016/S0749-8063(97)90185-7]
- [26] Sta H-U, Birrer S. The popliteus tendon and its fascicles at the popliteal hiatus: Gross anatomy and functional arthroscopic evaluation with and without anterior cruciate ligament deficiency. *Arthroscopy: The Journal of Arthroscopic & Related Surgery*. 1990; 6(3):209-20. [DOI:10.1016/0749-8063(90)90077-Q]
- [27] Hughston J, Andrews J, Cross M, Moschi A. Classification of knee ligament instabilities. Part II. The lateral. *The Journal of Bone and Joint Surgery. American Volume*. 1976; 58:173-9. [DOI:10.2106/00004623-197658020-00002] [PMID]
- [28] Bousquet G, Charmion L, Passot J, Girardin P, Relave M. Stabilisation du condyle externe du genou dans les laxités antérieures chroniques: Importance du muscle poplité [Stabilization of the external condyle of the knee in chronic anterior laxity: Importance of the popliteal muscle (French)]. *Revue de Chirurgie Orthopédique et Réparatrice de L'appareil Moteur*. 1986; 72(6):427-34. [PMID]
- [29] Shino K, Horibe S, Ono K. The voluntarily evoked posterolateral drawer sign in the knee with posterolateral instability. *Clinical Orthopaedics and Related Research*. 1987; (215):179-86. [DOI:10.1097/00003086-198702000-00026]
- [30] Staubli H, Jakob R. Posterior instability of the knee near extension. A clinical and stress radiographic analysis of acute injuries of the posterior cruciate ligament. *The Journal of Bone and Joint Surgery. British Volume*. 1990; 72(2):225-30. [DOI:10.1302/0301-620X.72B2.2312560] [PMID]
- [31] Davies H, Unwin A, Aichroth P. The posterolateral corner of the knee: Anatomy, biomechanics and management of injuries. *Injury*. 2004; 35(1):68-75. [DOI:10.1016/S0020-1383(03)00094-9]

- [32] Woodley, Mercer SR. Anatomy in practice: The Popliteus muscle. *New Zealand Journal of Physiotherapy*. Era 2010-2018; 34(1):25-9.
- [33] Muscolino JE. *The muscle and bone palpation manual with trigger points, referral patterns, and stretching*, 1st edition. Mosby, Elsevier Health Sciences; 2008.
- [34] Brody D. Techniques in the evaluation and treatment of the injured runner. *The Orthopedic Clinics of North America*. 1982; 13(3):541-58. [PMID]
- [35] Holmes JC, Pruitt AL, Whalen NJ. Iliotibial band syndrome in cyclists. *The American Journal of Sports Medicine*. 1993; 21(3):419-24. [DOI:10.1177/036354659302100316] [PMID]
- [36] Delee JC, Riley MB, Rockwood Jr CA. Acute posterolateral rotatory instability of the knee. *The American Journal of Sports Medicine*. 1983; 11(4):199-207. [DOI:10.1177/036354658301100403] [PMID]
- [37] Flynn JM, Wiesel SW. *Operative techniques in pediatric orthopaedics*. Philadelphia: Lippincott Williams & Wilkins; 2010.
- [38] Reichert B, Stelzenmueller W. *Palpation Techniques: Surface anatomy for physical therapists*, 1st edition. New York, : Thieme Medical Publishers; 2011.
- [39] De Smet AA, Asinger DA, Johnson RL. Abnormal superior popliteomeniscal fascicle and posterior pericapsular edema: Indirect MR imaging signs of a lateral meniscal tear. *American Journal of Roentgenology*. 2001; 176(1):63-6. [DOI:10.2214/ajr.176.1.1760063] [PMID]
- [40] Pavlov H, Goldman AB. The popliteus bursa: An indicator of subtle pathology. *American Journal of Roentgenology*. 1980; 134(2):313-21. [DOI:10.2214/ajr.134.2.313] [PMID]
- [41] Johnson RL, De Smet AA. MR visualization of the popliteomeniscal fascicles. *Skeletal Radiology*. 1999; 28(10):561-6. [DOI:10.1007/s002560050619] [PMID]
- [42] Dawson D-S. *Estimating and comparing proportions. Basic and clinical biostatistics* 2nd edition. Norwalk, Conn.: Appleton and Lange. 1990:142-60.
- [43] Hammer WI. *Functional soft-tissue examination and treatment by manual methods*. Massachusetts: Jones & Bartlett Learning; 2007.
- [44] Veltri D, Warren R. Anatomy, biomechanics, and physical findings in posterolateral knee instability. *Clinics in Sports Medicine*. 1994; 13(3):599-614. [PMID]
- [45] Suganuma J, Inoue Y, Tani H, Sugiki T, Sassa T, Shibata R. Reconstruction of the popliteomeniscal fascicles for treatment of recurrent subluxation of the lateral meniscus. *Arthroscopy Techniques*. 2017; 6(2):e283-e90. [DOI:10.1016/j.eats.2016.09.034] [PMID] [PMCID]
- [46] Fanelli GC, Larson RV. Practical management of posterolateral instability of the knee. *Arthroscopy: The Journal of Arthroscopic & Related Surgery*. 2002; 18(2):1-8. [DOI:10.1053/jars.2002.31779] [PMID]
- [47] Weiselfish-Giammatteo S. *Integrative manual therapy: For the upper and lower extremities*, Revised edition. Berkeley, CA: North Atlantic Books; 1998.
- [48] Webb DR. *Sports injuries: Diagnosis and management*. Philadelphia: Saunders; 1999.