

Review Article

Overview of Binocular Diplopia; Etiology, Assessment Methods, and Treatment Strategies

Yasir Adel Shakor¹, Razieh Bahreini^{2*}, Ali Majdi³

¹ Azadi Teaching Hospital Kirkuk, Iraq

² Vision Science Department, Pacific University College of Optometry, Forest Grove, Oregon, USA

³ Optical Techniques Department, College of Health and Medical Techniques, Al-Mustaqbal University, 51001, Babylon, Iraq

*** Corresponding author:** Razieh Bahreini, PhD.

Vision Science Department, Pacific University College of Optometry, Forest Grove, Oregon, USA

Tel:+1 971-429-9382

Email: bahr4360@pacificu.edu

ORCID ID:

Yasir Adel Shakor: 0009-0000-7446-1780

Razieh Bahreini: 0000-0002-0929-2623

Ali Majdi: 0000-0003-0528-6696

Article info:

Received: 29 Oct 2024

Accepted: 28 Dec 2024

Citation: Adel Shakor Y, Razieh B, Majdi A, Overview of Binocular Diplopia; Etiology, Assessment Methods, and Treatment Strategies. *Journal of Modern Rehabilitation*. 2025; 19(2):?-?

Running title: Binocular diplopia

Abstract:

Binocular diplopia is a challenging oculomotor disorder that significantly impacts patients' quality of life. This review provides a comprehensive overview of the etiology, diagnostic methods, and treatment strategies for binocular diplopia. Proper diagnosis begins with differentiating between monocular and binocular diplopia, followed by determining whether the cause is motor or sensory in nature. Diagnostic methods include detailed medical history, qualitative and quantitative assessment of diplopia, analysis using tools like the Haab Grid, evaluation of ocular motility, and assessment of head postures. The level of oculomotor defect should be investigated to differentiate between nuclear and supranuclear lesions. Treatment approaches are diverse and depend on the underlying cause. Functional strategies may include prismatic correction, which can provide immediate relief from diplopia. Surgical interventions are considered for cases of paralytic strabismus or when conservative measures are insufficient. The choice of treatment is guided by factors such as the etiology, duration, and severity of diplopia. Prismatic correction is often used as both a diagnostic tool and a treatment option, allowing for precise adjustment of eye alignment. In cases of acute diplopia, a systematic approach to diagnosis and appropriate identification of possible causes enables better patient management. This comprehensive approach to binocular diplopia, encompassing thorough diagnostic methods and a range of treatment strategies, aims to improve functional outcomes and enhance the quality of life for affected patients.

This study emphasizes the complexity of diplopia, distinguishing between monocular and binocular types, and motor and sensory forms. Management involves functional therapies, prismatic correction, and, if needed, botulinum toxin or surgery. Prompt evaluation and multidisciplinary collaboration are essential, particularly for neurological causes.

Keywords: Diplopia, Head tilt, Vertical deviation, Horizontal deviation, Strabismus surgery.

Introduction:

The double vision of objects in the environment (diplopia) which defied as the the perception of two images of a single object, is frequently the cause of the patient's disability, despite the subjective nature of this symptom.(1, 2) Diplopia considerably worsens patients' quality of life, leading to asthenopia complaints of different nature, difficulties in orientation, dizziness, i.e., loss of ability to work, professional difficulties, loss of the ability to drive vehicles, perform the precise motor and strenuous visual task. Torticollis or abnormal head postures (AHP), which usually accompanies diplopia, is a psychologically severe cosmetic defect.(3, 4) Binocular diplopia is a consequence of impaired coordination of eye movements or failure of the mechanism of binocular fusion of the two images at the brain level.(2) Therefore, the most frequent causes of its occurrence are, on the one hand, a malfunction of one or more extraocular muscles against the background of pre-existing normal binocular vision (motor diplopia), and, on the other hand, symmetric position restoration (after former strabismus) with a disruption of the fusion mechanism (sensory diplopia).(5, 6) However, it is not always possible to differentiate between the sensory factor in the origin of diplopia and the motor factor, especially for diplopia that occurs in the course of strabismus treatment. Therefore, a mixed form of diplopia is also possible to be observed in the clinical setting.(7)

Methods:

This comprehensive approach to binocular diplopia, encompassing thorough diagnostic methods and a range of treatment strategies, aims to improve functional outcomes and enhance the quality of life for affected patients. For this purpose, the terms “Diplopia”, “Head tilt”, “Vertical deviation”, “Horizontal deviation”, “Strabismus surgery”, and “Monocular and Binocular diplopia” were searched.

A bibliographic study of scientific publications with the keywords of this study was performed in the following databases: Medline, Cochrane, Scopus, and Google Scholar. A comprehensive search was conducted and the published books and papers from January 1932 to February 2023, included at least one of the keywords were included. The inclusion criteria now specify that only peer-reviewed articles published in English, focusing on binocular diplopia etiology, assessment methods, and treatment strategies, were included. Articles involving adult patients were prioritized, while pediatric cases were considered only if findings were generalizable. The exclusion criteria include studies published in languages other than English, those focused solely on monocular diplopia or pediatric populations, non-peer-reviewed literature (e.g., editorials, conference abstracts), and articles lacking sufficient data or relevance. These revisions have been incorporated into the manuscript for greater clarity and rigor.

Results:

Differentiation between monocular and binocular diplopia:

Monocular diplopia is most commonly caused by abnormalities in the optical system, e.g., cataract, corneal aberration, astigmatism, defective tear film, or higher-order aberration.(8-10) Monocular diplopia is characterized by a double image standing close to the fixed object. They may also overlap. Monocular diplopia persists when the unaffected eye is covered and disappears when the affected eye is covered or a stenopeic pinhole is applied.(10) However, binocular

diplopia disappears with occlusion of either the affected or the unaffected eye.(11). Previous research has indicated that the incidence of binocular diplopia ranges from 74.9% to 88.5% or less and it is less in monocular diplopia.(12).

Motor and sensory diplopia:

Diplopia can be the earliest manifestation of some very serious, life-threatening diseases (vascular, tumor, infectious, and other diseases of the brain and orbit, as well as systemic diseases).(13, 14) In recent years, the number of patients with these pathologies has increased due to the increase in the speed of vehicles and the advances in neurosurgery procedures.(15, 16) Neurosurgeons are able to save the lives of patients with conditions that were previously considered to be incompatible with life therefore, ophthalmologists are faced with the challenge of dealing with such serious complications as diplopia.(17)

Motor diplopia is most often caused by paresis or paralysis of the cranial nerve palsies, leading to the development of paralytic strabismus.(18) Predominantly, there is paralysis of the abducens nerve, since the abducens nerve passes through the entire base of the brain. Damage to the trochlear and oculomotor nerves is ranked second and third in terms of prevalence. (19) In motor diplopia, the mechanism of binocular vision is usually intact, and binocular image fusion is provided by turning the head toward the action of the paralyzed muscle that could shift the image in the strabismic eye to the central retinal area.(20)

Among the diseases affecting the central nervous system that cause diplopia, myasthenia gravis is the most common, while multiple sclerosis and progressive supranuclear ophthalmoplegia are less common. Peripheral lesions of the extraocular muscles contributing to pseudo-paralytic strabismus and associated with diplopia occur in endocrine myopathies and orbital traumas as a consequence of direct damage to the muscle.(21-23)

Sensory diplopia is associated with a congenital failure of the fusion mechanism or disorder.(24, 25) It is manifested when the symmetrical position of the eyes is disturbed. In this case, the image of the fixation object in one eye does not land on the central point of the retina but on the area adjacent to it, and the fusion mechanism fails to eliminate the displacement. In young children, due to the plasticity of the nervous system, functional inhibition rapidly occurs and diplopia disappears. When strabismus develops at a later age (usually after the age of four), diplopia may appear in a stronger form and persist for a longer period of time. Sensory diplopia can also occur after successful surgery when the bifixation mechanism is just beginning to become active or during functional diplopia treatment in children.(24, 26, 27) The latter is a favorable prognostic symptom indicating the possibility of binocular vision restoration.

Acute diplopia:

Acute diplopia leads to severe impairments in the form of blurred vision, dizziness, "missing the mark" and even the inability to work or drive. Affected patients usually consult an ophthalmologist promptly. For the practitioner, especially in the emergency service, it is important to assign the symptoms with respect to the time of onset and nature of diplopia for deriving a tentative diagnosis taking into account the differential diagnoses.(28, 29) This allows a targeted diagnosis, although it is not necessary to do multidisciplinary neurological work-up for every acute diplopia. (28, 30)

Discussion:

Diagnosis of diplopia:

Work up of diplopia includes the following factors:

- 1. Taking a medical history:* When establishing a medical history, attention is paid to the timing of diplopia, its relationship to past injuries and illnesses.

2. *Identifying the nature of diplopia:* With the aid cover test, it is necessary to ensure that diplopia occurs only when the two eyes are open. In this circumstance, the practitioner should examine that the diplopia is more pronounced while looking to the distance, near, or both. Diplopia should be checked in the principal directions of gaze (straight and down) and also in the secondary directions of gaze (right, left, up).
3. *Qualitative assessment of diplopia:* In this case, it is necessary to determine the direction of diplopia, including vertical and horizontal displacements or a mix of them. It should also be noted whether there is a rotational part or not.
4. *Quantitative assessment of diplopia:* This is performed by placing a loose prism in the test frame, turning the trial frame's wheel to achieve a coincidence of the double images, and determining the magnitude of prism diopters that could compensate diplopia.

It is also necessary to determine the impact of the ametropia-correcting spectacles on the nature of diplopia.

5. *Diagnostic analysis of diplopia:* Exploring diplopic images according to Haab's study is as follows. A transparent red lens is placed in front of the patient's right eye. The patient sitting on a chair, and the practitioner is at a distance of 1 meter from the patient, holding a flashlight with a slit - "Diplopic - L", in the way that the luminous strip was directed to the patient at the level of the eyes. The orientation of the slit depends on the type of diplopia: for horizontal diplopia, the slit is placed vertically, and for vertical diplopia - horizontally. The Haab Grid, a form with a square divided into nine equal blocks, is used to record the examination results. In the middle of each block, a strip with a length equal to 1/3 of the side of the block is drawn. The patient indicates to the doctor how the image of the displaced strip is located in relation to the one he or she is looking at. Next, the patient's indicated image is plotted in the center cell of the chart, taking into account the slope and horizontal and vertical displacement of the line. Then the flashlight is successively moved from the center 50 cm to the right, left, up, and down from the middle upper and lower positions; thus, an image of the relative position of the luminous bands in all 9 main directions of gaze is obtained. The examination is performed with the patient's head in a straight position. In each case, an image of the stripes is imaged in the corresponding block from the patient's report.

The following guidelines are used in evaluating the results of the test:

1. The muscle of that eye is affected, the image of which is further from the horizontal or vertical midline. This image is called imaginary.
2. The imaginary appearance is always projected in the direction of the action of the paralyzed muscle. Therefore, homonymous diplopia occurs when the muscles that deviate the eye to the outside (lateral rectus, superior oblique, and inferior oblique muscles) are affected; cross-eye diplopia occurs when the adductor muscles (medial rectus, superior rectus, and inferior rectus muscles) are affected.

In vertical diplopia: a) if the vertical separation of double images increases when looking up, one of the elevators of the eye whose image is higher is affected; b) if the vertical separation of double images increases when looking down, one of the depressors of the eye whose image is lower is affected.

3. The distance between the double images increases as the gaze moves toward the affected muscle.
6. *Determining the field of double vision and the field of single vision:* If the single vision is preserved in some direction, it can be examined with a special deviometry device.

A special tangential scale, designed to be viewed from a distance of 100 cm, is printed on the standard deviometry screen. The scale has a graduation value of 10 degrees from 0 to 50 degrees upward, downward, right, left, and along the four oblique meridians.(31)

The patient's head is placed in a straight position at 1 m distance from the screen and follows a vertical luminous strip, which the practitioner slowly moves from the center in 8 mentioned directions. They mark the points where the object begins to double and mark on a special form the field in which the patient sees merging images (the field of single vision) and the field in which the doubling of the vertical strip is marked (the field of doubling).

It is also possible to use the method of computer diagnostics of diplopia that combines deviometry and Haab's method.(32)

7. *Examination of the function of the oculomotor system:* Eye mobility is determined in 8 diagnostic positions of gaze; the affected muscle is determined by the evaluation of ductions and versions .(33, 34)

8. *Assessment of head postures:* When examining patients, special attention should pay to the head tilts and turns. The purpose of head rotation is to move the eye out of the area of double vision and action of the paralyzed muscle, i.e., the patient turns his head toward the affected muscle.

In vertical motor palsy, the position of the head is determined by a combination of 3 positions:

- 1) raising or lowering the head;
- 2) tilting the head toward the right or left shoulder;
- 3) turning the face to the right or left side.

Correction of the horizontal separation of images when the thevertical-action muscles are affected is achieved by turning the face to the right or left side. In this regard, the vertical muscles are divided into 2 groups, adjacent in pairs to the adductors (upper and lower rectus muscles) and to the abductors (upper and lower oblique muscles). Therefore, if each of them is paralyzed, a horizontal rotation of the head is observed to the side that corresponds to the paralysis of the adductor or abductor of the same eye. For example, when the superior oblique muscle of the right eye is paralyzed, in addition to lowering the head downward and tilting to the left shoulder, the head must also be turned to the right side (the latter, as in the case of the right abductor paralysis).

9. *Investigation of the level of oculomotor defect:* Since impaired oculomotor muscle function may be a consequence of neurological pathology, differential diagnosis of the nuclear and supranuclear levels of oculomotor lesions is mandatory.

The vestibulo-ocular reflex (the "doll's head" test) and Bell's phenomenon(35, 36) are two tests determining the etiology of a gaze palsy; whether the lesion is "nuclear" or "supranuclear".

The "doll's head" phenomenon is characterized by the presence of complete mobility and symmetrical excursion of the eyeballs when tilting and turning the head in combination with complete external ophthalmoplegia.(35, 37) This means that it is possible to contract the extraocular muscles and their innervation nuclei are intact. Thus, the absence of voluntary eye movements with preserved refractory movements indicates pathology of the efferent signal to the oculomotor nuclei, i.e., to the supranuclear level of the defect.

Normally, the Bell's phenomenon manifests itself as a deviation of the eyeball upwards when the eyelids are closed. In patients with oculomotor nerve lesions, a positive Bell's phenomenon is detected when the eyelids are open passively at the moment of their full contraction.(38) The absence of voluntary upward eye movements with preserved Bell's phenomenon indicates a supranuclear level of oculomotor lesion.

Sensory disorders associated with diplopia in the absence of ocular movement disorders:

The occurrence of sudden diplopic images does not necessarily require an eye movement disorder (**Figure 1**). (39) The so-called comitant strabismus, in which no double images are usually perceived as an early childhood concomitant strabismus, is characterized by the fact that all muscles of both eyes have unrestricted movement ability, i.e., the monocular field of vision is

usually not restricted.(40) The strabismus angle is constant in the different directions of gaze without significant angular differences. Furthermore, the comitant strabismus angle does not depend on which eye is dominant (primary and secondary strabismus angles are identical.(41, 42) When double vision occurs, the main challenge of the ophthalmologist is to perform the suitable treatment (prism compensation, surgical correction) as soon as possible after history taking and orthoptic examination in order to preserve the ability of single binocular vision.(43) The main reasons for developing sensory acute diplopia are summarized in **Table 1**.

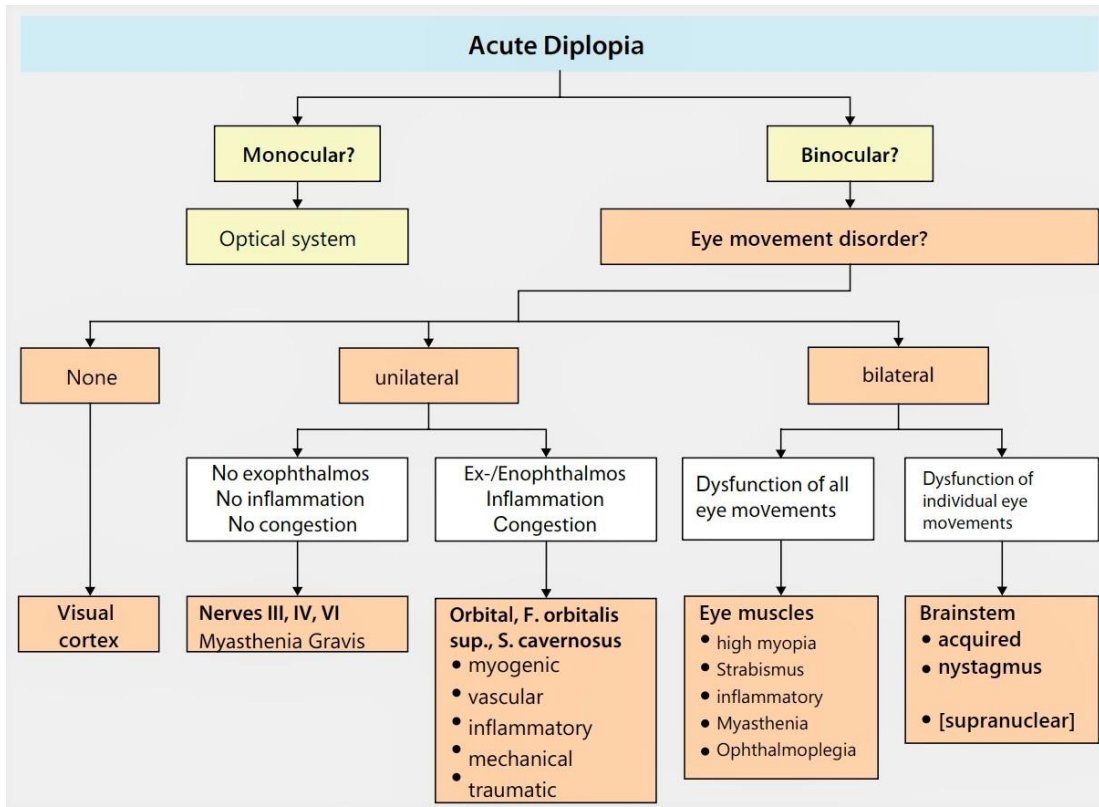


Figure 1: The diagnostic algorithm in acute diplopia

Table 1: Sensory disorders with acute diplopia without eye movement disorders. Diagnostic characteristics and urgency of a primary neurological work-up and/or MRI.

Sensory disorders with acute diplopia	Characteristics and treatment plan	Primary neurological work-up/MRI?
<i>Sensory strabismus</i>	<p>The onset of strabismus with comitant esotropia after 3 years, initially no amblyopia.</p> <p>Exclusion of another cause (e.g. retinoblastoma).</p> <p>Medical history, photo history.</p> <p>Neurological symptoms? Squinting of one eye?</p> <p>Prompt prism compensation and surgery to</p>	<p>No, only in case of accompanying neurological symptoms</p>

	preserve stereopsis.	
<i>Decompensated phoria</i>	<p>Mostly decompensated comitant esophoria or exophoria, previously often diplopia in case of fatigue, rarely also traumatically decompensated.</p> <p>In the case of exophoria, compensation via accommodative convergence (4-prism base-in test) if necessary, observe pupillomotor function, refraction compensation, and improvement of symptoms under the use of Marlow occlusion.</p>	No
<i>Congenital superior oblique palsy</i>	<p>In adduction, comitant vertical deviation, low incomitant cyclotropia, head tilt involvement with the same magnitude in upward and downward gaze, increased vertical fusion range as a sign of long persistence, facial asymmetry, photo history helpful as often well compensated by head constraint posture over several years.</p> <p>Diplopia in adduction of the affected eye</p>	No
<i>Accommodation-convergence spasm</i>	<p>Near vision spasm, blurred vision rather than double vision. It can cause an apparent abduction deficit.</p> <p>Observe pupillomotor function.</p> <p>Therapy with atropine, bifocals, lens tinting, and therapy for underlying mental disorders.</p>	No
<i>Postoperative diplopia</i>	After surgical interventions on the eye or the eye muscles in case of over- or under-correction	No
<i>Fusion loss</i>	<p>Mostly after craniocerebral trauma, more rarely retinal surgery, no superimposition of images possible, occlusions or "spectacle miscorrections" can be tried, look for individual solutions</p>	No
<i>Suppression loss</i>	<p>Loss of suppression, for example, after occlusion therapy, after multiple extraocular muscle operations with position changes, after late operations of early acquired cataracts, occlusions or "spectacle miscorrections" can be tried, and individual solutions sought.</p>	No

Unilateral eye movement disorders with diplopia

Binocular diplopia may be associated with restricted movement of one eye. However, infranuclear motility disorders are ocular movement disorders caused by lesions below the cranial nerve nuclei, i.e., in the cranial nerves, orbit, or extraocular muscles.

Extraocular muscle paresis (acquired lesions of oculomotor cranial nerves and ocular myasthenia) is often the cause of diplopia.(44, 45) Paralytic strabismus is characterized by incomitant

strabismus with an increase in double images and strabismus angle when looking to the direction of the paretic muscle. The maximum amount of motility is limited unilaterally. Therefore, a characteristic of paralytic strabismus is the increase of the strabismus angle when changing fixation from the nonparetic eye (primary strabismus angle) to fixation with the paretic eye (secondary strabismus angle).(19, 46) The secondary strabismus angle during fixation with the paretic eye is larger than the primary strabismus angle (fixation with the healthy eye) due to the increased innervation effort in the straight gaze. Since the strabismus angle decreases significantly when looking to the opposite direction of the paretic muscle. The patient adopts a compensatory head posture to avoid diplopia.(19) The head is rotated in the direction of contraction of the paretic muscle (e.g., right lateral rectus muscle palsy causes head turn to the right).

The onset and character of binocular double vision give clues for its etiology; therefore, besides determining the strabismus angle in different fields of vision and attention to accompanying signs, the exact taking of a medical history plays an important role. The ophthalmologist's task is to characterize the movement disorder and additional accompanying symptoms in order to narrow down the location and type of lesion as precisely as possible and to specifically initiate the necessary further diagnostics in other specialties. A supranuclear disorder should definitely be excluded if the motility deficit can be localized or only individual types of movement are disturbed.

Unilateral eye movement disorders with diplopia without accompanying local signs

1. Extraocular muscle paresis syndrome

Sudden double vision is characteristic of neurogenic disorders of the extraocular muscles.(19) Extraocular muscle palsies are the isolated oculomotor, trochlear, or abducens paresis. They show the typical characteristic of incomitant paralytic strabismus without restrictive, myopathic, myasthenic, or other orbital signs.

i. Acquired isolated oculomotor (3th) nerve palsy:

The oculomotor nerve innervates several extraocular muscles (inferior rectus, medial rectus, superior rectus, inferior oblique, and levator palpebrae) as well as the internal eye muscles (sphincter muscle of pupil and ciliary muscle). Depending on the severity of the damage, different forms of paralysis result in:(47, 48)

- External ophthalmoplegia: Only the external eye muscles are affected. The clinical signs are complete ptosis, divergent eye position with limited ability to adduction, elevation and depression.
- Internal ophthalmoplegia: only the internal eye muscles are affected. the clinical signs are sphincter paralysis with paretic mydriasis, anisocoria (with an increase in light) and paralysis of accommodation,
- Complete external and/or internal oculomotor palsy. Complete failure of all external and/or internal ocular muscles.

The most common cause of isolated oculomotor palsy is ischemia of the third cranial nerve vasa vasorum.(49) include diabetes mellitus, arterial hypertension, and old age.

Vascular oculomotor palsy may be preceded by retrobulbar pain or temporal headache, and often the pupillary fibers are spared due to their superficial location compared to compressive third nerve palsy.(50, 51)

For diagnosis the condition, further neurologic evaluation and prompt imaging is always required for isolated oculomotor nerve palsy if:

- The patient is younger than 60 years or is a child,
- Presence of additional neurological deficits
- The pupillary fibers are involved

- The gradual development of signs and symptoms that cause suspicion of a slow-growing pathology (e.g., tumors).

Neurologic evaluation and imaging are required for work-up of most isolated oculomotor nerve palsy except for particular old patients with appropriate risk factors.

ii. ***Acquired isolated abducens (6th) nerve palsy:***

The abducens nerve palsy results in abduction limitation with esotropia and uncrossed diplopia that increases when looking to the side of the paralyzed muscle.(52, 53) The strabismus angle is greater at a distance than near, resulting in diplopia that is first noticed when looking out the window and driving.

The most common cause of isolated abducens palsy in elderly patients is ischemia of the vessels supplying the nerve (risk factors: diabetes mellitus, arterial hypertension, age).(54) Less common causes are demyelinating diseases or trauma, inflammation, or tumors in the region of the clivus and petrous bone, which lead to compression or stretching of the nerve. Vascular abducens palsy usually resolves within three months. Acquired isolated abducens palsy may happen spontaneously after viral infections or even after vaccination in children.

iii. ***Acquired isolated trochlear (4th) nerve palsy***

The trochlear nerve has a long intracranial route from its origin at the back of the brainstem; in addition, it runs extraconally in the orbital cavity close to the orbital roof, which means that the chance for injuries lesion is remarkable.(55) A lesion of the trochlear nerve leads to a depression deficit in adduction with vertical and often tilted double images (excyclotropia), which increase in gaze and when looking to the nonparetic side, due to the obliquus superior paresis.(56, 57) In unilateral trochlear nerve palsy, the head is compensatory tilted and rotated to the unaffected side with or without the chin held in down position. In addition, the Bielschowsky head tilt test is positive.(58)

The causes follow the 10-20-30-40-rule: 10% neoplasm/aneurysm, 20% ischemia, 30% idiopathic or rare causes (multiple sclerosis, herpes zoster, etc.), 40% trauma.(59, 60) Diagnostic criteria are comparable with other nerve palsies.

Treatment of isolated neurogenic ocular muscle paresis depends on the cause. Therefore, a causative treatment strategy (e.g., neurosurgical tumor removal) is suggested.(58) From the clinical point of view, only symptomatic patients need to be treated. Generally, prism compensation is usually not possible due to incomitance and cyclotropy (61). It is also recommended to wait for spontaneous recovery for at least six months before surgical intervention.(58)

iv. ***Ocular myasthenia:***

The manifestation of diplopia while fatigue or alternating findings suggest ocular myasthenia, especially if ptosis exists at present or before.(62) It can alternately cause all forms of eye movement disorders and ptosis, unilateral as well as bilateral; paresis of one cranial nerve or the presentation of several paralyzes simultaneously.(63, 64) In most cases, ocular motility abnormalities are the first symptom of systemic disease.(65)

The exclusion of pupillary or optic involvement and the absence of accompanying orbital signs support this diagnosis. Positive serum acetylcholine antibodies prove myasthenia.(66) A positive Simpson test (Ice bag test) for ptosis and a positive Tensilon test could suggest ocular myasthenia. Exclusion of a thymoma by imaging is mandatory. Further neurological diagnosis and initiation of therapy by neurologist [cholinesterase inhibitors (e.g. pyridostigmine plus corticosteroids) are indicated.(67) This usually leads to remarkable improvement of the symptoms.(68)

Treatment of binocular diplopia:

Treatment of patients with binocular diplopia is complex and includes both functional and surgical methods.(43, 44)

Patients can be treated for diplopia in the following ways:

1. **Treatment of the underlying disease, referring the patient to an appropriate specialist.**
2. **Prismatic correction.** Achieved with prismatic glasses or plastic (Fresnel) prisms. The prismatic action is a deviation of the beam to the base and displacement of the image to the top of the prism.

Spectacles with prismatic corrections are prescribed and fabricated together with spectacles correcting ametropia. Fresnel prisms are prepared in the doctor's office from ready-made standard industrial prisms, which are cut out with scissors to the shape of the frame and adhered (after soaking in water) to the back surface of the patient's spectacles.(69, 70)

Prismatic spectacles with a prism power of more than 12 PD (6 PD in each eye) are poorly tolerated by patients because they are quite heavy and often cosmetically unacceptable. Therefore, if a larger prismatic power is necessary, Fresnel prisms are recommended. These are available up to 40 PD but for control of diplopia mostly use up to 20 PD. However, one should keep in mind that starting from 15 PD. However, the Fresnel prisms significantly affect visual acuity quality and give the sensation of "rainbow spots" near the edges of the objects.(71)

Prescription of prismatic correction is aimed at eliminating diplopia in the main directions of gaze - straight ahead and downward. Therefore, after fitting prisms, the single vision field should be checked.(69, 72) In addition, prismatic correction of diplopia can improve the quality of life and reading performance of the affected patients.(73)

3. **Functional treatment:** All kinds of orthoptic exercises are designed to restore fusion capability and normal binocular vision.(74)
4. **Reflexology therapy and physical therapy.** There is a sufficient range of various physiotherapeutic procedures that can be applied in the complex treatment of binocular diplopia.(75, 76)
5. **Chemodenervation therapy by botulinum toxin.** In some selected cases, chemodenervation therapy has been used as compensation for ocular misalignments that induce diplopia. Although this minimally invasive method can be very helpful, appropriate case selection is mandatory, and it is usually used in patients with small angle deviation. .(77, 78)
6. **Surgical treatment.** Strabismus surgery for diplopic patients is an indication for cases with a large angle of deviation in which prismatic correction, botulinum toxin injection and functional therapies are ineffective .(77, 79) Surgical treatment of diplopia is not indicated for double vision in the extreme gaze directions (lateral, upper, lower, or oblique) if there is no double vision in the primary eye position and the symmetrical eye position is maintained.(77)

The most severe form of diplopia is torsional diplopia or cyclo-diplopia.(80) It is a diplopia with perceived skewed objects in the environment and accompanied by a forced rotation of the head (ocular torticollis).(81) Torsional diplopia occurs when there is an imbalance between a pair of muscles that are intortors (superior rectus and superior oblique muscles) or a pair of muscles that are extortors (inferior rectus and inferior oblique muscles).(82, 83)

The causes of torsional diplopia are:

- traumas and concussions of the brain;
- Combined traumas of the brain and eyeball;
- acquired vertical motor paresis (as a consequence of oculomotor muscle imbalance during surgical interventions for strabismus surgeries)

Cyclodiplopia associated with cyclodeviation; investigation and treatment

In patients with spontaneous diplopia, cyclodeviation (cyclodiplopia) can be roughly determined using a ruler.(63) The ruler is placed horizontally in front of the patient's eyes, slightly below the

midline. If one of the cyclovertical muscles is affected, vertical doubling of the ruler is noted. When the patient covers his eyes alternately, he determines to which eye the upper or lower image of the ruler belongs and then determines from which side both lines seem closer to each other (on the left or right).

The double Maddox-rod test has been used to prove and quantify the degree of cyclodeviation.(84) Two Maddox rod lenses (red and white or green) are placed in front of the eyes in a vertical position. By the inclination character of red and white stripes, as in the previous technique, it is judged on the property of the diplopia. By turning the lens (in the trial frame) in front of the eye which has the oblique image, its parallelism with the horizontal image of the other eye is achieved and the degree of cyclodeviation is defined simply by reading the number of distortion (which is included on the trial frame) or according to the Technischer Ausschuss für BrillenOptik (TABO) scale in degrees.(85) This test may trigger diplopia at the time of examination, although doubling may be absent in natural conditions.(86) A straight position of the head and correction of patient's refraction at the time of examination is important.

Bagolini striated lenses can be placed in the frame to investigate cyclodeviation in conditions approximating natural ("light" dissociation, without color separation of visual fields). The axis of the fringes should correspond to 90 degrees.(87) If the patient does not merge the two vertical lines, the glasses are rotated until fusion occurs. The degree of deviation and diplopia in this method may be less than in the assessment of the magnitude of cyclodeviation with Maddox lenses due to the less dissociating effect of the Bagolini striated lenses.(87)

These methods are based on the fact that the retinal images of the horizontal line of the fixating and deviated eyes do not coincide and are tilted in relation to each other. Tilting the horizontal line downward toward the nose reveals excyclodeviation, as the vertical meridian is tilted outward and the nasal part of the horizontal meridian becomes higher than its temporal end when the eyeball is extorted. Tilting the horizontal line down toward the temple reveals incyclodeviation accordingly (the vertical meridian deviates to the inside and the nasal end of the horizontal meridian becomes lower than the temporal end). An easy-to-remember principle is that the line always tilts in the direction that the impaired muscle would rotate the eye if it operated in isolation.

A complex framework including surgical, functional, and combined methods is used to treat patients with cyclodiplopia. The goal of treatment is to restore the cooperation of both eyes by developing a fusion and bifixation mechanism.(88)

Functional treatment of cyclodiplopia:

Different steps for functional treatment of cyclodiplopia are:

1. Development of binocular fusion in conditions of forced head rotation. The ideal form of a test object to begin treatment is a circle (circumference); since patients have cyclodiplopia and cyclotropia, it seems impossible to merge figures having angles and lines. The size of the test objects should correspond to the average angular dimensions of retinal zones:

- foveal: 1.3 degrees;
- parafoveal: 2.5 degrees;
- macular:5.0 degrees.

This method displays test objects on a transparent plastic plate (paired tests) as zonal tests. These objects are presented in the area where oculomotor muscle function is least affected, guided by Haab double image study, single vision field, and the patient's subjective perception.

The ratio of distances to the tests and between the tests is selected in which there is a complete fusion of the test objects, by moving the test objects at different distances from the patient's eyes, changing the head position and the angle of gaze. The criterion for binocular fusion is the appearance of a binocular visual image, an imaginary third circle located between the two presented objects.

2. ***Development of the fusional amplitude (range):*** After achieving fusion of the test objects in a certain zone, a complete divergence and convergence are developed in this zone, at least in the forced position of the head. Further, binocular fusion is achieved even when the head is straight.

3. ***Developing fusion in different gaze positions:*** With the straight position of the head attained, develop fusion in other positions by shifting the tests and turning the head (horizontally and vertically).

4. ***Development of fusion and expansion of the fusional amplitude using test objects - geometric shapes of varying degrees of complexity:***

- octagon;
- hexagon;
- diamond;
- triangle with the orientation of the vertex up and down;
- rectangle;
- square.

The exercises are done for 30 minutes (5 minutes a session and 2-3 minutes a break). The shape of geometric shapes of the test is changed as stable fusion is achieved. The next change of the test depends on the individual ability of the patient. In some cases, with good fusion ability, the transition from one form of the test to another is achieved after 5-10 sessions, in other cases, with weak fusion ability, after 10-20 sessions.

Functional treatment is most effective in patients with trauma and concussion of the brain when the injury persists for 1-6 months.

Overall, two types of surgeries are used in the surgical treatment of diplopia including:

First, operations on the muscles involved in strengthening or weakening their action and

-second, operations that provide a change in the rotational action of the muscles by shifting the sites of their attachments. If surgical handling has not acceptable effect on the remove of diplopia, the residual diplopia may manage with postoperative functional treatment.(89) The proposed system of functional, surgical, and combined treatment of binocular diplopia contributes to a significant improvement in the state of visual functions and the quality of life of patients.(90)

This study underscores the complexities of diplopia and its profound impact on patients' quality of life, emphasizing the critical importance of accurate diagnosis and individualized management strategies. Diplopia, whether monocular or binocular, arises from diverse etiologies, including optical system abnormalities, neurological disorders, and systemic diseases. Distinguishing between motor and sensory diplopia is essential for effective treatment, as they involve distinct mechanisms and clinical presentations. Acute diplopia, often signaling serious underlying pathologies, demands prompt evaluation using detailed history-taking, quantitative assessments, and advanced diagnostic techniques such as Haab's method and deviometry.

Management of binocular diplopia involves a multifaceted and structured approach aimed at restoring binocular single vision and enhancing quality of life. This includes addressing the underlying cause through targeted interventions or specialist referrals. Functional therapies, such as orthoptic exercises and physical treatments, improve fusion capability and binocular vision, while prismatic correction using spectacles or Fresnel prisms serves as a mainstay treatment. Chemodenervation therapy with botulinum toxin and strabismus surgery are reserved for cases where functional and prismatic methods prove insufficient, with surgery specifically indicated for large-angle deviations.

Multidisciplinary collaboration is crucial in managing complex cases, particularly those with neurological origins, as advancements in neurosurgery have increased the prevalence of diplopia as a complication. A structured framework integrating functional rehabilitation, precise

diagnostics, and surgical interventions significantly enhances visual outcomes and patient well-being.

A systematic approach and appropriate identifications of the possible causes of diplopia allow the ophthalmologist to better patient management. Skillful investigation of ocular motilities will permit proper treatment of the underlying abnormality. The examiner should be familiar with the diplopia nature and be able to use the simplest and least invasive method to eliminate the diplopia. Future research should focus on refining diagnostic tools, deepening the understanding of the neuro-ophthalmological mechanisms underlying diplopia, and exploring innovative treatments to preserve or restore binocular vision. Additionally, long-term studies on the efficacy of combined therapeutic modalities in both sensory and motor diplopia cases are vital for establishing evidence-based guidelines and improving patient care and outcomes.

Acknowledgments:

We would like to express our sincere gratitude to the numerous researchers and authors whose work contributed to this comprehensive review. We are particularly indebted to Dr. Yasir Adel Shakor as a first author, Dr. Razieh Bahreini as a corresponding author and for the valuable comments. Additionally, we acknowledge the valuable feedback provided by Dr. Ali Majdi during the manuscript review process, which significantly enhanced the quality of this work.

Authors contributions:

Yasir Adel Shakor conceptualized and designed the review, conducted the literature search, and curated the data. Ali Majdi and Yasir Adel Shakor contributed to drafting the manuscript and performed critical revisions for intellectual content. Razieh Bahreini and Yasir Adel Shakor provided supervision, reviewed the final draft, and ensured the scientific rigor of the work. Razieh Bahreini conducted the publication process. All authors contributed to discussions, and revisions, read, and approved the final version.

Conflicting interests:

The authors declared no potential conflicts of interest with respect to the research, authorship, and publication of this article.

Funding

This study was conducted without any internal/external funding or financial support.

References:

1. Beauchamp GR, Black BC, Coats DK, Enzenauer RW, Hutchinson AK, Saunders RA, et al. The management of strabismus in adults—III. The effects on disability. *Journal of American Association for Pediatric Ophthalmology and Strabismus*. 2005;9(5):455-9.
2. Glisson CC. Approach to diplopia. *Continuum: Lifelong Learning in Neurology*. 2019;25(5):1362-75.
3. LEVIN IM. Ocular torticollis in children. *American Journal of Diseases of Children*. 1932;44(5):1026-39.
4. Singh A, Parihar J, Maggon R, Kumar S, Mishra S, Badhani A. Chronic acquired ocular torticollis: A diagnostic dilemma. *medical journal armed forces india*. 2017;73(1):91-3.
5. Comer R, Dawson E, Plant G, Acheson J, Lee J. Causes and outcomes for patients presenting with diplopia to an eye casualty department. *Eye*. 2007;21(3):413-8.

6. Nazerian P, Vanni S, Tarocchi C, Portaccio E, Vannucci N, Para O, et al. Causes of diplopia in the emergency department: diagnostic accuracy of clinical assessment and of head computed tomography. *European Journal of Emergency Medicine*. 2014;21(2):118-24.
7. Dulayajinda D, Kosrirukvongs P, Songcharoen S. Causes of diplopia. *Journal of the Medical Association of Thailand= Chotmai-het Thangphaet*. 1991;74(8):323-8.
8. Fincham E. Monocular diplopia. *The British Journal of Ophthalmology*. 1963;47(12):705.
9. Records RE. Monocular diplopia. *Survey of Ophthalmology*. 1980;24(5):303-6.
10. Iuz R, Korniusheva T. Monocular diplopia. *Vestnik Oftalmologii*. 1991;107(3):39-44.
11. Jain S. Diplopia: Diagnosis and management. *Clinical Medicine*. 2022;22(2):104.
12. Kumar N, Kaur S, Raj S, Lal V, Sukhija J. Causes and outcomes of patients presenting with diplopia: a hospital-based study. *Neuro-Ophthalmology*. 2021 Jul 4;45(4):238-45.
13. Sreedhar A, Menon A. Understanding and evaluating diplopia. *Kerala Journal of Ophthalmology*. 2019;31(2):102.
14. Wang Z, Zhu B, Fu L, Yan J. Etiology and clinical features of diplopia in south china: analysis of 303 cases. *Frontiers in Neurology*. 2022;12:2653.
15. Kernich CA. Diplopia. *The Neurologist*. 2006;12(4):229-30.
16. Kaeser P-F, Klainguti G. Management of diplopia secondary to neurosurgical injury of the orbital roof. *Klinische Monatsblätter für Augenheilkunde*. 2008;225(05):507-9.
17. Kim H-J, Kim H-J, Choi J-Y, Yang HK, Hwang J-M, Kim J-S. Diplopia: characteristics and etiologic distribution in a referral-based university hospital. *Journal of Neurology*. 2022:1-9.
18. Kawai M, Goseki T, Ishikawa H, Hoshina M, Shoji N. Causes, background, and characteristics of binocular diplopia in the elderly. *Japanese journal of ophthalmology*. 2018;62:659-66.
19. Sowka J. Neurogenic diplopia: paralysis of cranial nerves III, IV, and VI. *Optometry Clinics: the Official Publication of the Prentice Society*. 1996;5(3-4):53-76.
20. Cornblath WT. Diplopia due to ocular motor cranial neuropathies. *CONTINUUM: Lifelong Learning in Neurology*. 2014;20(4):966-80.
21. Apers R, Bierlaagh J. Indications and results of eye muscle surgery in thyroid ophthalmopathy. *Ophthalmologica*. 1976;173(3-4):171-9.
22. Flanders M. Restrictive strabismus: diagnosis and management. *American Orthoptic Journal*. 2014;64(1):54-63.
23. Kremmyda O, Frenzel C, Hufner K, Goldschagg N, Brem C, Linn J, et al. Acute binocular diplopia: peripheral or central? *Journal of neurology*. 2020;267:136-42.
24. Pratt-Johnson J, Tillson G. The loss of fusion in adults with intractable diplopia (central fusion disruption). *Australian and New Zealand journal of ophthalmology*. 1988;16(2):81-5.
25. Clark JT. Obstacles to fusion: Strabismus and diplopia. *American Orthoptic Journal*. 2008;58(1):14-7.
26. Sharma M, Hunter DG, editors. *Diplopia after strabismus surgery*. *Seminars in Ophthalmology*; 2018: Taylor & Francis.

27. Khan AO, Al-Shamsi H. Binocular diplopia following vision restoration in patients with keratoconus and sensory strabismus. *Strabismus*. 2008;16(1):19-22.
28. Merino P, Fuentes D, de Liaño PG, Ordonez M. Binocular diplopia in a tertiary hospital: aetiology, diagnosis and treatment. *Archivos de la Sociedad Española de Oftalmología (English Edition)*. 2017;92(12):565-70.
29. Raucci U, Parisi P, Vanacore N, La Penna F, Ferro V, Calistri L, et al. Acute diplopia in the pediatric Emergency Department. A cohort multicenter Italian study. *European Journal of Paediatric Neurology*. 2017;21(5):722-9.
30. Kelbsch C, Besch D, Wilhelm H. Acute diplopia: Differential diagnosis and treatment options. *Klinische Monatsblätter für Augenheilkunde*. 2017;234(11):1348-53.
31. Grenga PL, Reale G, Cofone C, Meduri A, Ceruti P, Grenga R. Hess area ratio and diplopia: evaluation of 30 patients undergoing surgical repair for orbital blow-out fracture. *Ophthalmic Plastic & Reconstructive Surgery*. 2009;25(2):123-5.
32. Yoo HS, Park E, Rhiu S, Chang H-J, Kim K, Yoo J, et al. A computerized red glass test for quantifying diplopia. *BMC ophthalmology*. 2017;17:1-6.
33. Clement R. Computer simulation of extraocular muscle co-operation: an evaluation. *Ophthalmic and Physiological Optics*. 1982;2(2):107-17.
34. Zhuang R, Sun H, Bian H. A new method of learning the function of the extraocular muscles. *Clinical Anatomy*.
35. Buettner U, Zee D. Vestibular testing in comatose patients. *Archives of neurology*. 1989;46(5):561-3.
36. FRACO ICF, DOBA JAL. Bell's phenomenon: a study of 508 patients. *Australian Journal of Ophthalmology*. 1984;12(1):15-21.
37. Foster CA, Foster BD, Spindler J, Harris JP. Functional loss of the horizontal doll's eye reflex following unilateral vestibular lesions. *The Laryngoscope*. 1994;104(4):473-8.
38. Mustafa TA. The Bell's phenomenon in newborns. *Neurosciences Journal*. 2005;10(1):41-3.
39. O'Colmain U, Gilmour C, MacEwen CJ. Acute-onset diplopia. *Acta Ophthalmologica*. 2014;92(4):382-6.
40. Oystreck DT, Lyons CJ. Comitant strabismus: Perspectives, present and future. *Saudi Journal of Ophthalmology*. 2012;26(3):265-70.
41. Burian HM, Capobianco NM. Monocular diplopia (binocular triplopia) in concomitant strabismus. *AMA Archives of Ophthalmology*. 1952;47(1):23-30.
42. Posner A, Schlossman A. Relation of diplopia to binocular vision in concomitant strabismus. *AMA Archives of Ophthalmology*. 1951;45(6):615-22.
43. Iliescu DA, Timaru CM, Alexe N, Gosav E, De Simone A, Batras M, et al. Management of diplopia. *Romanian journal of ophthalmology*. 2017;61(3):166.
44. Rucker JC, Tomsak RL. Binocular diplopia: a practical approach. *The neurologist*. 2005;11(2):98-110.
45. Suh SY, Clark RA, Le A, Demer JL. Extraocular muscle compartments in superior oblique palsy. *Investigative Ophthalmology & Visual Science*. 2016;57(13):5535-40.
46. Harley RD. Paralytic strabismus in children: etiologic incidence and management of the third, fourth, and sixth nerve palsies. *Ophthalmology*. 1980;87(1):24-43.

47. Raza HK, Chen H, Chansysouphanthong T, Cui G. The aetiologies of the unilateral oculomotor nerve palsy: a review of the literature. *Somatosensory & motor research*. 2018;35(3-4):229-39.
48. Kaido T, Tanaka Y, Kanemoto Y, Katsuragi Y, Okura H. Traumatic oculomotor nerve palsy. *Journal of clinical neuroscience*. 2006;13(8):852-5.
49. Blake PY, Mark AS, Kattah J, Kolsky M. MR of oculomotor nerve palsy. *American journal of neuroradiology*. 1995;16(8):1665-72.
50. Yanovitch T, Buckley E. Diagnosis and management of third nerve palsy. *Current opinion in ophthalmology*. 2007;18(5):373-8.
51. BRAZIS PW, editor *Localization of lesions of the oculomotor nerve: recent concepts*. Mayo Clinic Proceedings; 1991: Elsevier.
52. Elder C, Hainline C, Galetta SL, Balcer LJ, Rucker JC. Isolated abducens nerve palsy: update on evaluation and diagnosis. *Current neurology and neuroscience reports*. 2016;16:1-7.
53. Geçirilmesi G. Review of a series with abducens nerve palsy. *Turkish Neurosurgery*. 2008;18(4):366-73.
54. Jung JS, Kim DH. Risk factors and prognosis of isolated ischemic third, fourth, or sixth cranial nerve palsies in the Korean population. *Journal of Neuro-Ophthalmology*. 2015;35(1):37-40.
55. Burgerman RS, Wolf AL, Kelman SE, Elsner H, Mirvis S, Sestokas AK. Traumatic trochlear nerve palsy diagnosed by magnetic resonance imaging: case report and review of the literature. *Neurosurgery*. 1989;25(6):978-81.
56. Probst RL, Majetschak M. Traumatic unilateral trochlear nerve palsy. *Journal of Trauma and Acute Care Surgery*. 2007;62(6):E1-E3.
57. Choi K-D, Choi SY, Kim J-S, Choi J-H, Yang T-H, Oh S-Y, et al. Acquired ocular motor nerve palsy in neurology clinics: a prospective multicenter study. *Journal of Clinical Neurology*. 2019;15(2):221-7.
58. Diora JR, Plager DA. Sudden-onset trochlear nerve palsy: clinical characteristics and treatment implications. *Journal of American Association for Pediatric Ophthalmology and Strabismus*. 2019;23(6):321. e1-. e5.
59. Khanam S, Sood G. *Trochlear Nerve Palsy*. 2020.
60. Mehlan J, Schüttauf F. Infranuclear Eye Movement Disorders. *Klinische Monatsblätter für Augenheilkunde*. 2021;238(11):1178-85.
61. Altintas A. Trochlear nerve palsy: a review of etiology, incidence, diagnostic methods, and treatment alternatives. *Arch Neurol Neurosci*. 2020;7:1-5.
62. Smith SV, Lee AG. Update on ocular myasthenia gravis. *Neurologic Clinics*. 2017;35(1):115-23.
63. Holmes JM, Leske DA, Kupersmith MJ. New methods for quantifying diplopia. *Ophthalmology*. 2005;112(11):2035-9.
64. Nair AG, Patil-Chhablani P, Venkatramani DV, Gandhi RA. Ocular myasthenia gravis: a review. *Indian journal of ophthalmology*. 2014;62(10):985.
65. Al-Haidar M, Benatar M, Kaminski HJ. Ocular myasthenia. *Neurologic clinics*. 2018;36(2):241-51.
66. Peeler CE, De Lott LB, Nagia L, Lemos J, Eggenberger ER, Cornblath WT. Clinical utility of acetylcholine receptor antibody testing in ocular myasthenia gravis. *JAMA neurology*. 2015;72(10):1170-4.

67. Benatar M, Kaminski H. Medical and surgical treatment for ocular myasthenia. Cochrane Database of Systematic Reviews. 2006(2).
68. Fortin E, Cestari DM, Weinberg DH. Ocular myasthenia gravis: an update on diagnosis and treatment. *Current opinion in ophthalmology*. 2018;29(6):477-84.
69. Gunton KB. Prism use in adult diplopia. *Current Opinion in Ophthalmology*. 2012;23(5):400-4.
70. Flanders M, Sarkis N. Fresnel membrane prisms: clinical experience. *Canadian journal of ophthalmology Journal canadien d'ophtalmologie*. 1999;34(6):335-40.
71. Vicente GV. Prisms in Ophthalmic Optics. *Optics for the New Millennium: An Absolute Review Textbook*: Springer; 2022. p. 15-32.
72. Tamhankar MA, Ying G-s, Volpe NJ. Success of prisms in the management of diplopia due to fourth nerve palsy. *Journal of neuro-ophthalmology: the official journal of the North American Neuro-Ophthalmology Society*. 2011;31(3):206.
73. Hatt SR, Leske DA, Liebermann L, Holmes JM. Successful treatment of diplopia with prism improves health-related quality of life. *American journal of ophthalmology*. 2014;157(6):1209-13.
74. Singman EL, Matta NS, Silbert DI. Nonsurgical treatment of neurologic diplopia. *American Orthoptic Journal*. 2013;63(1):63-8.
75. Wahid A, Nossier A, Saif M, Taher S, Abouelnaga W. Physical therapy interventions for reduction of ocular deviation after strabismus surgery. *Physiotherapy Quarterly*. 2022;30(1):33-8.
76. Ludwig IH, Clark RA, Stager Sr DR. New strabismus surgical techniques. *Journal of American Association for Pediatric Ophthalmology and Strabismus*. 2013;17(1):79-88.
77. Phillips PH, editor *Treatment of diplopia*. *Seminars in neurology*; 2007: Copyright© 2007 by Thieme Medical Publishers, Inc., 333 Seventh Avenue, New
78. Granet DB, Hodgson N, Godfrey KJ, Ventura R, Kikkawa DO, Levi L, et al. Chemodenervation of extraocular muscles with botulinum toxin in thyroid eye disease. *Graefe's Archive for Clinical and Experimental Ophthalmology*. 2016;254:999-1003.
79. Eckstein A, Esser J, Oeverhaus M, Saeed P, Jellema HM. Surgical treatment of diplopia in Graves orbitopathy patients. *Ophthalmic Plastic & Reconstructive Surgery*. 2018;34(4S):S75-S84.
80. Miller AM. Torsional diplopia. *American Orthoptic Journal*. 2015;65(1):21-5.
81. Escuder AG, Kazlas MA, Heidary G, Hunter DG, Zurakowski D, Dagi LR. Incidence of symptomatic vertical and torsional diplopia after superior rectus transposition for esotropic Duane syndrome and abducens nerve palsy. *Journal of American Association for Pediatric Ophthalmology and Strabismus*. 2020;24(5):270. e1-. e5.
82. Garrity JA, Saggau DD, Gorman CA, Bartley GB, Fatourehchi V, Hardwig PW, et al. Torsional diplopia after transantral orbital decompression and extraocular muscle surgery associated with Graves' orbitopathy. *American journal of ophthalmology*. 1992;113(4):363-73.
83. Serafino M, Fogagnolo P, Trivedi RH, Saunders RA, Nucci P. Torsional diplopia after orbital decompression and strabismus surgery. *European journal of ophthalmology*. 2010;20(2):437-41.

84. Peragallo JH, Newman NJ, editors. Diplopia—An Update. Seminars in Neurology; 2016: Thieme Medical Publishers.
85. Brazis PW, Lee AG, editors. Binocular vertical diplopia. Mayo Clinic Proceedings; 1998: Elsevier.
86. Marsh JD, Durkin MW, Hack AE, Markowitz BB, Cheeseman EW. Accuracy of double Maddox rod with induced hypertropia in normal subjects. American Orthoptic Journal. 2014;64(1):76-80.
87. Ruttum M, Von Noorden G. The Bagolini striated lens test for cyclotropia. Documenta Ophthalmologica. 1984;58:131-9.
88. von Noorden GK. Clinical and theoretical aspects of cyclotropia. SLACK Incorporated Thorofare, NJ; 1984. p. 126-32.
89. Bartiss MJ. Nonsurgical treatment of diplopia. Current opinion in ophthalmology. 2018;29(5):381-4.
90. McBain HB, Au CK, Hancox J, MacKenzie KA, Ezra DG, Adams GG, et al. The impact of strabismus on quality of life in adults with and without diplopia: a systematic review. Survey of Ophthalmology. 2014;59(2):185-91.